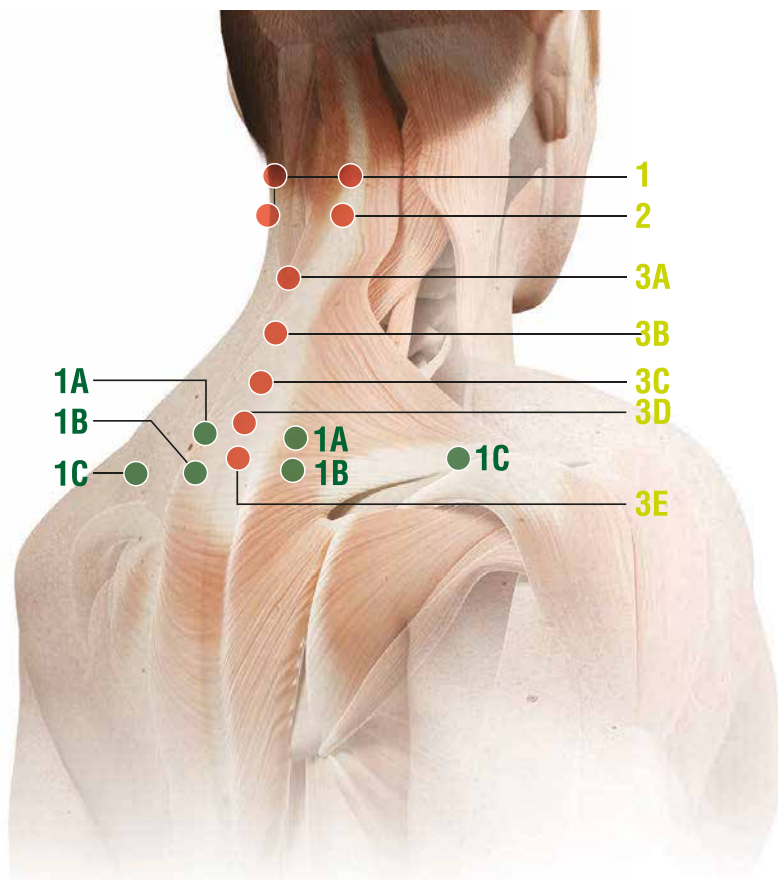
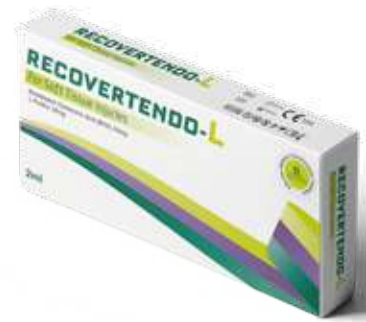

THERAPEUTIC ATLAS

RECOVERTENDO-L






CERVICAL REGION



Remarks:

Subcutaneous (**s.c.**) and intradermal injections: use a 12-16mm, 25-28G needle.

Intramuscular (**i.m.**) injections: use a 40mm, 21G needle

- When making subcutaneous injections, insert the needle at approximately a 45° degree angle ( 45°)
- When making intradermal injections, insert the needle at approximately a 30° degree angle ( 30°)
- When making intramuscular injections, insert the needle at approximately a 90° degree angle ( 90°)

● SECONDARY POINTS

1

Anatomical landmarks:

- A) 3-4 cm lateral to the space between the spinous processes of C6 and C7 (bilateral)
- B) 3-4 cm lateral to the space between the spinous processes of C7 and T1 (bilateral)
- C) midway along the line joining the spinous process of C7 and the acromion.

How to inject: i.d. at a depth of 5-6 mm.

● MAIN POINTS

1

Anatomical landmark:

Below the external occipital protuberance, in the muscle insertion, just below the transverse process of the atlas.

How to inject: s.c.

2

Anatomical landmarks:

3-4 cm lateral to the space between the spinous processes of C2 and C3.

How to inject: s.c.

3

Anatomical landmarks:

- From the top:

- A) below the spinous process of C2
- B) below the spinous process of C4
- C) below the spinous process of C5
- D) below the spinous process of C6
- E) below the spinous process of C7.

How to inject: i.d.

CERVICAL REGION

- Injection in the **main points**

• Neck pain due to cartilage degenerative cervical spine disorders (cervical osteoarthritis):

• Neck pain due to cervical muscular trigger points:

• Stiff neck syndrome:

• Neck pain due to muscle tension:

• Whiplash:

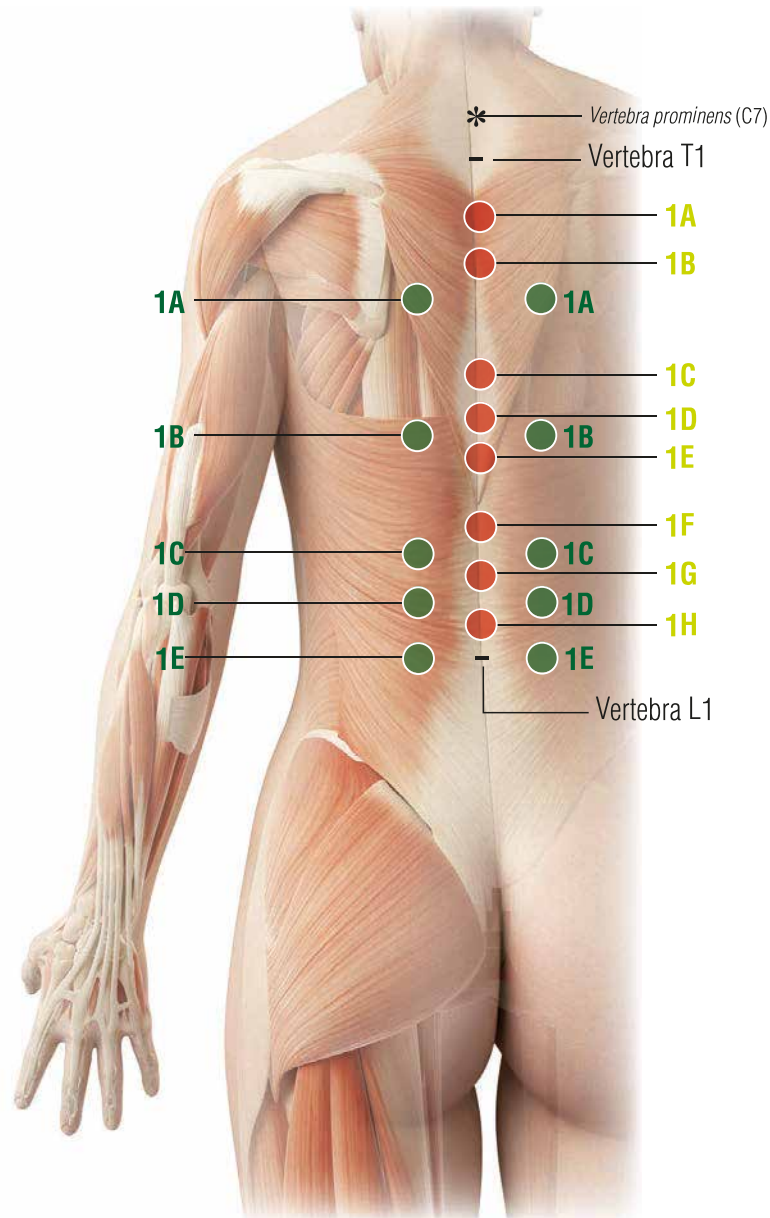
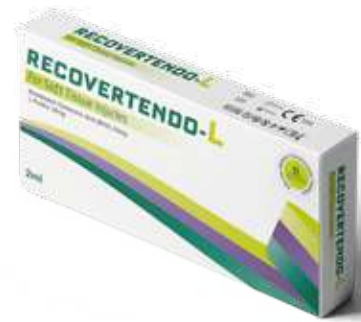• Postural neck ache:

• Mechanical imbalance (facet joint syndrome):



• Cervical spinal ligament syndrome:

• Cervical spinal nerve root pain:

THORACIC REGION



Remarks:

- For the numbering of the spinous processes of the vertebrae indicated in Main Points and Secondary Points, you can start from the vertebra prominens*: spinous process of C7; in full anterior cervical flexion this is the main and most prominent landmark.
It's the most important landmark of the whole spine.
- Subcutaneous (**s.c.**) and intradermal (**i.d.**) injections: use a 12-16mm, 25-28G needle.
 - When making subcutaneous injections, insert the needle at approximately a 45 degree angle ( 45°)
 - When making intradermal injections, insert the needle at approximately a 30 degree angle ( 30°)

● SECONDARY POINTS

1

Anatomical landmarks:

- From the top:

- A) 3-4 cm lateral to the space between the spinous processes of T3 and T4
- B) 3-4 cm lateral to the space between the spinous processes of T7 and T8
- C) 3-4 cm lateral to the space between the spinous processes of T10 and T11

D) 3-4 cm lateral to the space between the spinous processes of T11 and T12

E) 3-4 cm lateral to the space between the spinous processes of T12 and L1.

How to inject: s.c.

● MAIN POINTS

1

Anatomical landmarks::

- From the top:

- A) below the spinous process of T2
- B) below the spinous process of T3
- C) below the spinous process of T6
- D) below the spinous process of T7

E) below the spinous process of T8

F) below the spinous process of T10

G) below the spinous process of T11

H) below the spinous process of T12.

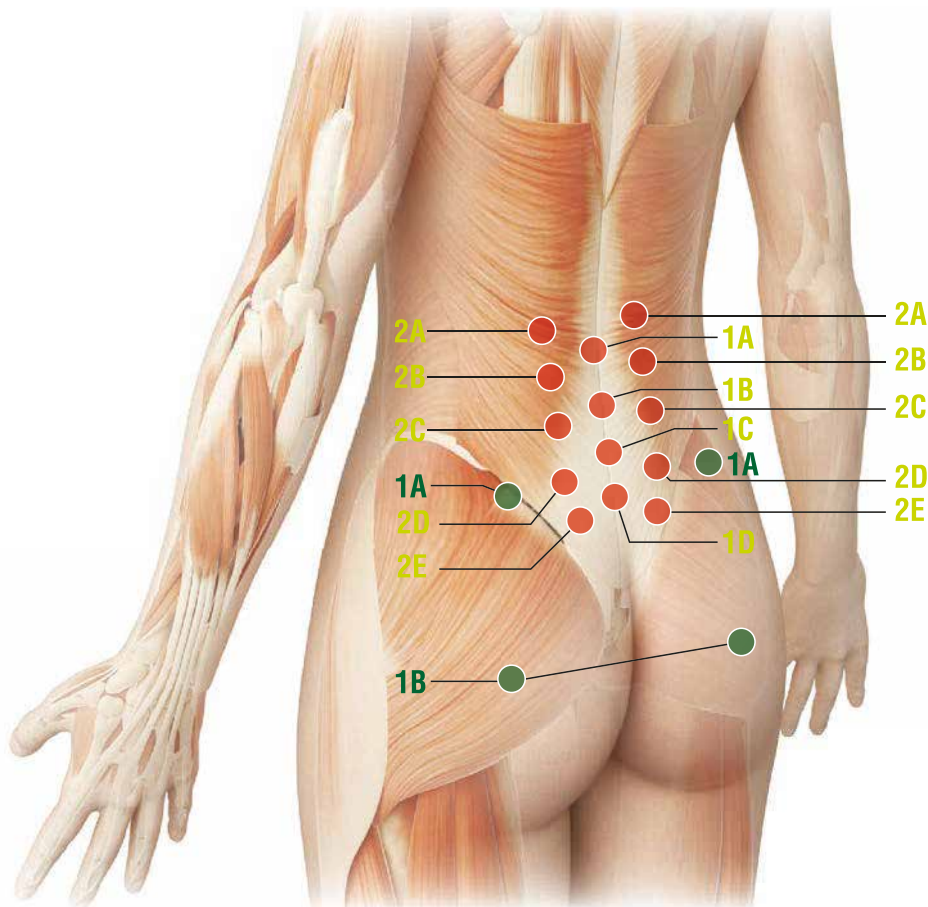
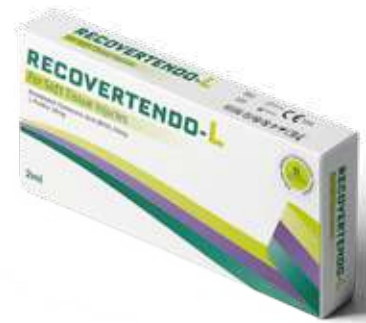How to inject: i.d.

THORACIC REGION

- Injection in the **main points**

- Thoracic pain due to cartilage degenerative thoracic spine disorders (thoracic osteoarthritis and arthritis):
 - Thoracic pain due to scoliosis:
 - Thoracic pain due to thoracic long muscle trigger points:
 - Pain due to thoracic spine osteophytosis:
- Thoracic pain due to spinal osteoporosis: MD-Thoracic + MD-Neural + MD-Muscle
- Mechanical imbalance (costo-vertebral facet joint syndrome):
 - Thoracic spinal ligament syndrome:
 - Thoracic spinal nerve root pain:




LUMBAR REGION



Remarks:

Subcutaneous (**s.c.**) and intradermal injections: use a 12-16mm, 25-28G needle.

Intramuscular (**i.m.**) injections: use a 40mm, 21G needle

- When making subcutaneous injections, insert the needle at approximately a 45° angle ()
- When making intradermal injections, insert the needle at approximately a 30° angle ()
- When making intramuscular injections, insert the needle at a 90° angle ()

● SECONDARY POINTS

1

Anatomical landmarks:

A) On the iliac crest, approximately 8-10 cm from the posterior midline.

How to inject: s.c. or i.d.

B) In the middle of the gluteus maximus muscle, at the same line of the anatomical landmark A1 (see above).

How to inject: i.m., at a depth of 2.5-3 cm.

● MAIN POINTS

1

Anatomical landmarks:

- From the top:

A) below the spinous process of L2

B) below the spinous process of L3

C) below the spinous process of L4

D) below the spinous process of L5.

How to inject: i.d. or s.c.

2

Anatomical landmarks:

- From the top:

A) 5-6 cm lateral to the space between the spinous processes of L1 and L2

B) 5-6 cm lateral to the space between the spinous processes of L2 and L3

C) 5-6 cm lateral to the space between the spinous processes of L3 and L4

D) 5-6 lateral to the space between the spinous processes of L4 and L5

E) 3-4 cm lateral to the space between the spinous processes of L5 and S1.

How to inject: i.m. at a depth of 10-12 mm.

LUMBAR REGION

- Injection in the **main points**

• Lumbar pain secondary to cartilage degenerative lumbar spine disorders (lumbar and lumbar-sacral arthrosis):

• Lumbar vertebral osteophytosis:

• Low-back pain secondary to musculo-tendinous trigger points:

• Postural low-back aches:

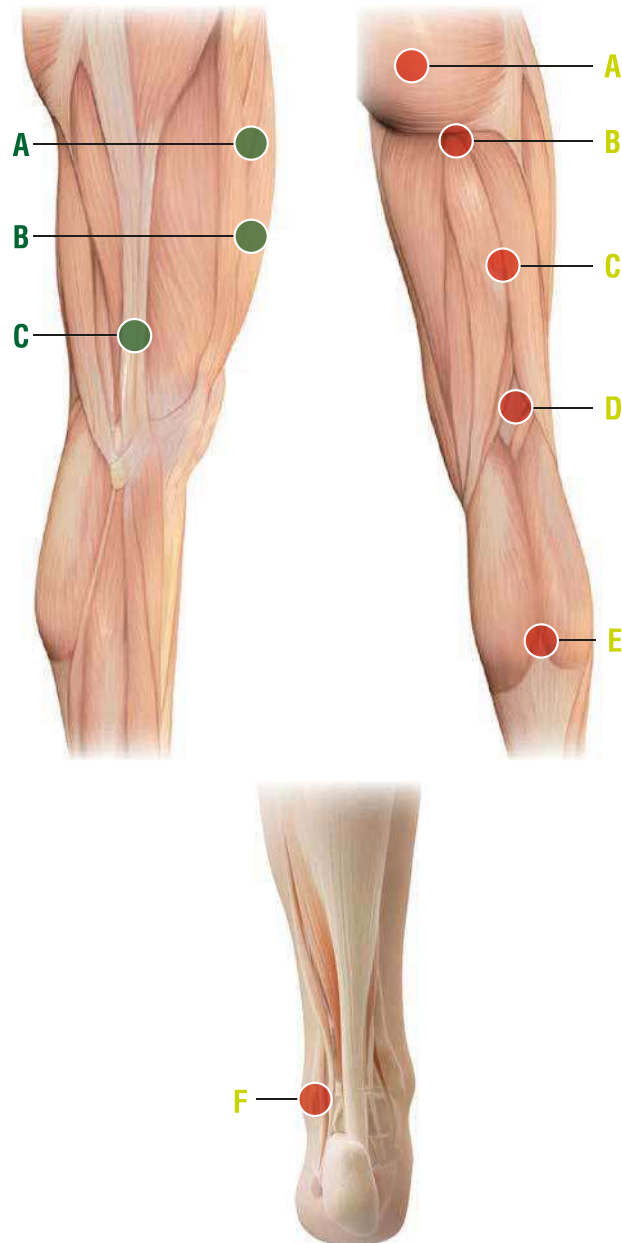
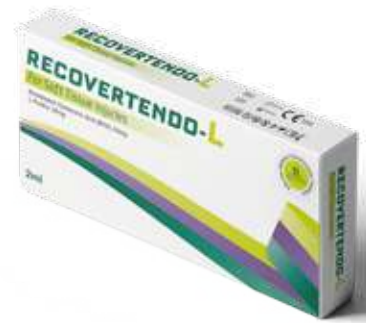• Lumbar and lumbar-sacral mechanical imbalance:

• Lumbar and lumbar-sacral spinal ligament syndrome:

• Sacro-iliac syndrome:

• Spinal lumbar and lumbar-sacral nerve root pain:

ISCHIAL NERVE



Remarks:

Subcutaneous (**s.c.**) and intradermal injections: use a 12-16mm, 25-28G needle.

Intramuscular (**i.m.**) injections: use a 40mm, 21G needle

- When making subcutaneous injections, insert the needle at approximately a 45 degree angle ($\sphericalangle_{45^\circ}$);
- When making intradermal injections, insert the needle at approximately a 30 degree angle ($\sphericalangle_{30^\circ}$);
- When making intramuscular injections, insert the needle at approximately a 90 degree angle ($\sphericalangle_{90^\circ}$).

● SECONDARY POINTS

Anatomical landmarks:

- A) Midway of the anterior thigh, about 20 cm above the upper edge of the patella
- B) Midway of the anterior thigh, about 15 cm above the upper edge of the patella.

How to inject: s.c.

How to inject: i.m. or s.c.

- C) Patient standing straight, on the lateral surface of the thigh, at the point where the patient's middle finger touches the thigh.

● MAIN POINTS

Anatomical landmarks:

- A) Midway of the gluteus maximus muscle, 5-6 cm lateral from the posterior midline
- B) Midway of the gluteal-femoral fold
- C) Midway of the posterior surface of the thigh, midway between the anatomical landmark B (see above) and the anatomical landmark D (see below)
- D) Midway of the popliteal crease
- E) Point of intersection between the two

muscles of the gastrocnemius and the tendon of the soleus muscle

- F) 3-4 cm from the tip of the lower and posterior external malleolus.

How to inject:

A, B and C : i.m.

D: i.d.

E, F: s.c.

ISCHIAL NERVE

- Injection in the **main points**

- Sciatic pain:
- Lumbar-sciatic pain:
- Nerve pain in the lower lumbar spine:
- Persistent sciatic pain due to post-surgery treatment of disc herniation L4-L5, L5-S1:
- Morton's neuroma:

● SECONDARY POINTS

1

Anatomical landmarks:

- A) The highest point of the anterior axillary fold
- B) Point of intersection between the supraspinatus muscle and the posterior aspect of the acromion
- C) 7 cm lateral to the spinous process of C7

D) Highest point of the posterior axillary fold.

How to inject: i.m. at a the depth of 0.8 - 1 cm.

● MAIN POINTS

1

Anatomical landmarks:

Lateral-external surface of the shoulder, in the acromioclavicular joint, the dimple that is formed by lifting the arm.

How to inject: s.c., i.d., i.a.

2

Anatomical landmark:

Midway of the segment joining the acromioclavicular joint to the highest point of the anterior axillary fold (Secondary point 1A).

How to inject: Peri-articular injection at a 90 degree angle to the skin surface, very close to the joint capsule.

- Alternatively: s.c.

3

Anatomical landmark:

Upper limb in horizontal position; postero-external surface, in the dimple that is formed between the acromion and the greater tubercle of the humerus.

How to inject: Peri-articular injection at a 90 degree angle to the skin surface, very close to the joint capsule.

- Alternatively: s.c.

4

Anatomical landmark:

On the vertical line drawn through the posterior axillary fold (Secondary point 1D), in the dimple of the posterior aspect of the shoulder joint.

How to inject: i.m., s.c.

5

Anatomical landmarks:

1) The shoulder joint (glenohumeral joint) can be injected in the anterior, lateral and upper aspect. It is generally easier to access in these locations.

- The lateral approach 5A and posterior approach 5B are the most used in ambulatory care

2) The acromioclavicular joint is easy to access.

- The approach can be posterosuperior (5C).

How to inject: Intra-articular.

A common standard needle for i.m. injection can be easily used.

SHOULDER

- Injection in the **main points**

- Shoulder-arm polyarthritis:

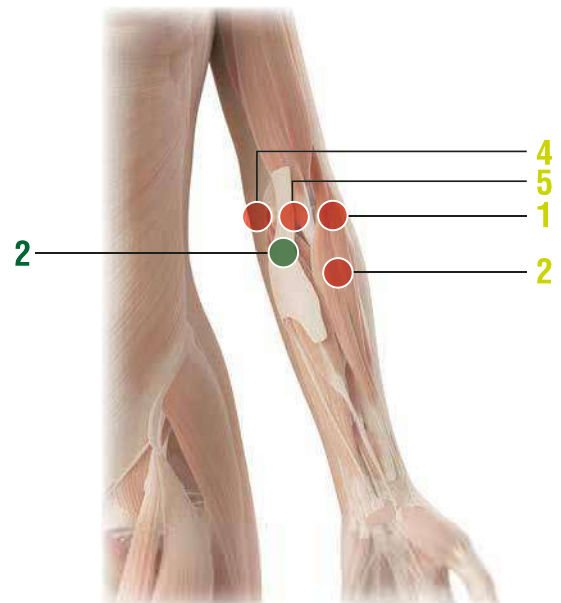
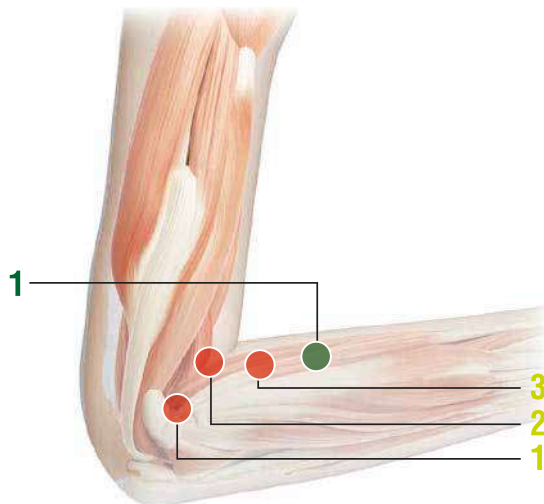
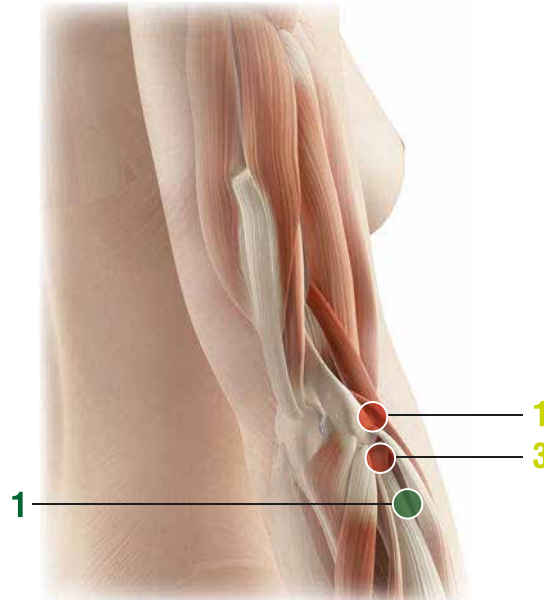
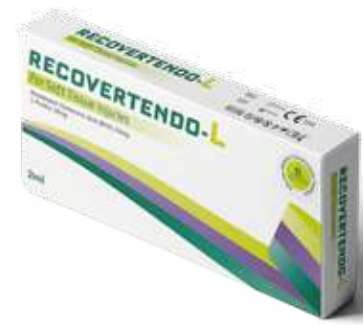- Rotator cuff syndrome:

- Shoulder-arm syndrome:

- Frozen shoulder:

- Shoulder pain due to dislocation (pre and post relocation):




ELBOW



Remarks:

Subcutaneous (**s.c.**) and intradermal injections: use a 12-16mm, 25-28G needle.

Intramuscular (**i.m.**) injections: use a 40mm, 21G needle

- When making subcutaneous injections, insert the needle at approximately a 45 degree angle( 45°
- When making intradermal injections, insert the needle at approximately a 30 degree angle( 30°
- When making intramuscular injections, insert the needle at approximately a 90 degree angle( 90°

● SECONDARY POINT

EPICONDYLITIS

1

Anatomical landmark:
2-3 cm more distal from the anatomical landmark 2 of the main Points.

How to inject: s.c. or i.m.
(at a depth of 5-6 mm).

EPITROCHLEITIS

2

Anatomical landmark:
The midway point of the elbow crease, on the internal side of the biceps tendon.

How to inject: s.c. or i.d.

● MAIN POINTS

EPICONDYLITIS

1

Anatomical landmark:
Elbow flexed at a 90 degree angle, just in front of the epicondyle.

How to inject: s.c. at a 90 degree angle to the bone surface.

2

Anatomical landmark:
At the external tip of the folded elbow flexed at a 90 angle.

How to inject: s.c. or i.m. (at a depth of 5-6 mm).

3

Anatomical landmark:
Elbow flexed at a 90 degree angle approximately 4 cm in front of the anatomical landmark 2.

How to inject: s.c. or i.m. (at a depth of 5-6 mm).

EPITROCHLEITIS

4

Anatomical landmark:
On the posteroanterior aspect of the elbow, between the medial condyle of the humerus (trochlea) and the olecranon.

How to inject: s.c. at a 90 degree angle to the bone surface.

5

Anatomical landmark:
At the tip of the internal crease of the elbow flexed at a 90 degree angle.

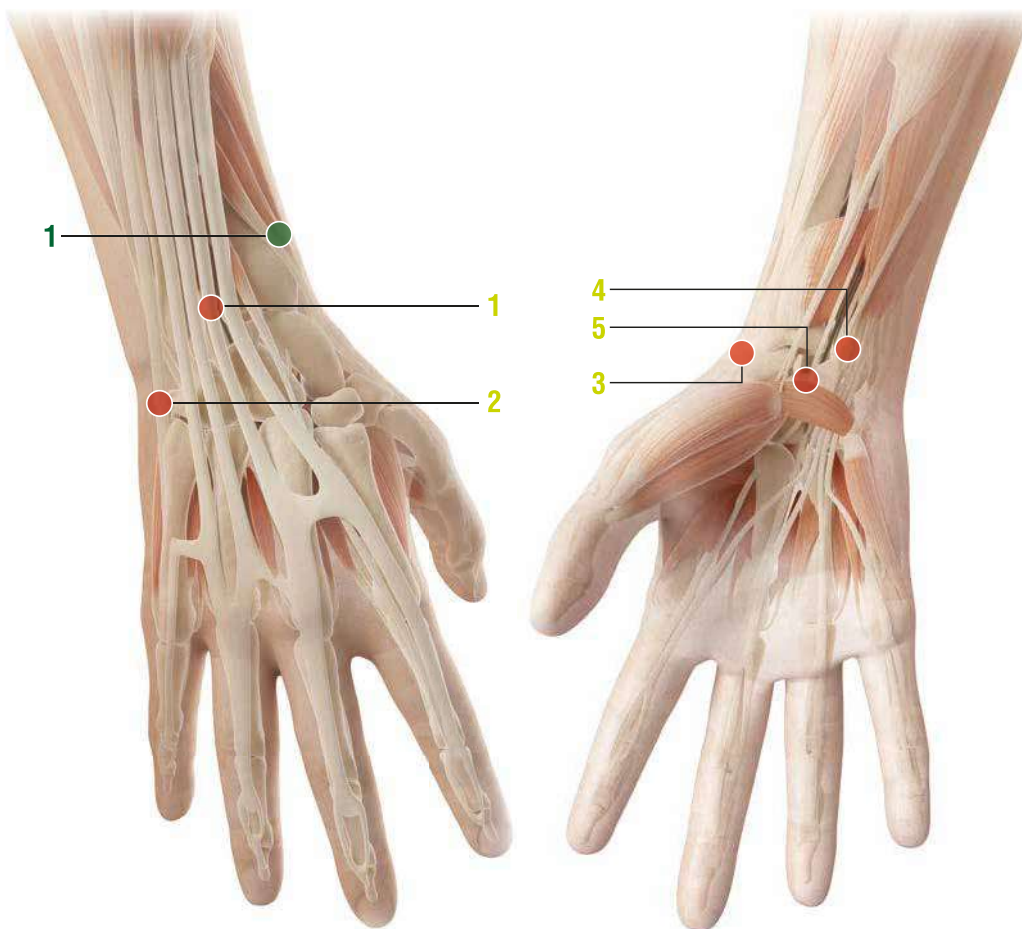
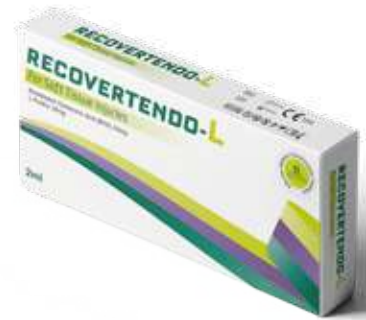How to inject: s.c. or i.m. (at a depth of 4-5 mm).

ELBOW

- Injection in the **main points**

- Epicondylitis
- Epitrochleitis
- De Quervain syndrome (stenosing tenosynovitis):

WRIST



Remarks:

Subcutaneous (s.c.) and intradermal injections: use a 12-16mm, 25-28G needle.

- When making subcutaneous injections, insert the needle at approximately a 45 degree angle ($\sphericalangle_{45^\circ}$);
- When making intradermal injections, insert the needle at approximately a 30 degree angle ($\sphericalangle_{30^\circ}$);

● SECONDARY POINT

1

On the external edge of the radius (proximal to the dorsal surface of the forearm), approximately 6-7 cm from the flexion crease of the wrist.

How to inject: s.c.

● MAIN POINTS

1

Anatomical landmark:
On the dorsal surface of the forearm, approximately 2 cm above the dorsal crease of the wrist, on the internal side of the radius (hand in a supinated position).

How to inject: s.c.

2

Anatomical landmark:
On the internal border of the hand, in a dimple between the 5th metacarpal and the hamate bone.

How to inject: s.c.

3

Anatomical landmark:
In the radial depression, on the flexion crease of the wrist.

On the external border of the hand in a dimple, above the head of the 1st metacarpal bone.

How to inject: s.c.

4

Anatomical landmark:
2 cm above the flexion crease of the wrist, between the pisiform bone and styloid process of the ulna.

How to inject: s.c.

5

Anatomical landmark:
Midway of the flexion crease of the wrist.

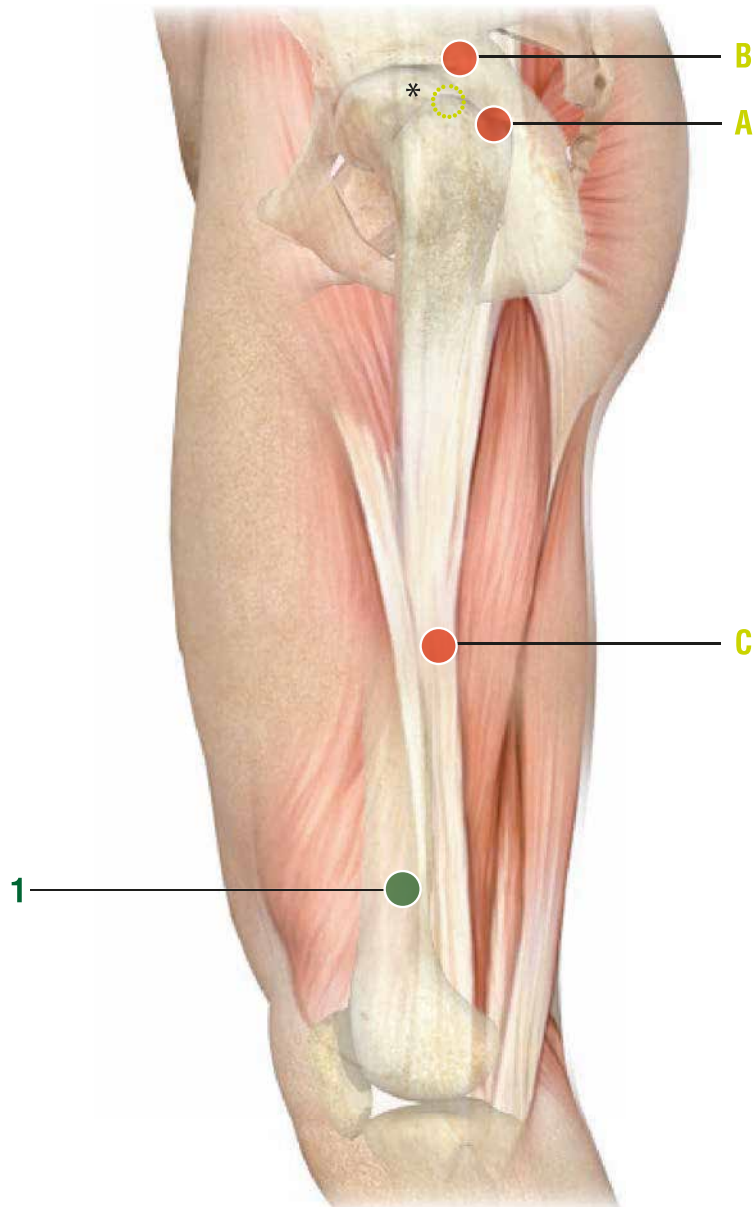
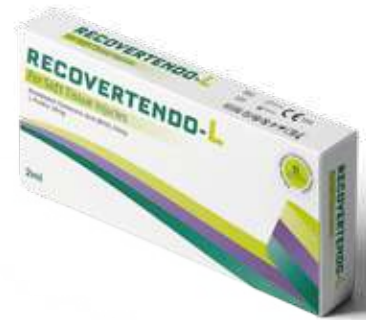How to inject: s.c.

WRIST

- Injection in the **main points**

- Arthritis of the fingers (local painful points):
- Rhizarthrosis of the thumb (Forestier disease):
- Carpal-tunnel syndrome:
- De Quervain disease
- Rheumatoid arthritis of the hand:
- Hand tendon pain due to prolonged immobilization:

HIP



Note:

Subcutaneous (**s.c.**) and intradermal injections: use a 12-16mm, 25-28G needle.

Intramuscular (**i.m.**) injections: use a 40mm, 21G needle

Intra-articular injections: use a dedicated needle.

- When making subcutaneous injections, insert the needle at approximately a 45 degree angle (∠_{45°});
- When making intramuscular injections, insert the needle at approximately a 90 degree angle (∠_{90°}).

● SECONDARY POINT

1

Anatomical landmark:
8 cm above the external femoral condyle.

How to inject: i.m. at a depth of 1 cm, insert the needle at a 90 degree angle to the skin surface
- Alternatively: s.c.

● MAIN POINTS

Anatomical landmark:

- A) Patient in orthostatic position with feet together, posterior margin of the greater trochanter. With patient lying on the healthy side, the anatomical landmark is localized on the apex of the greater trochanter*.
- B) 2 cm above and in front of the highest margin of the greater trochanter (anatomical landmark A).
- C) Patient in orthostatic position: upper limb along the trunk, point on the thigh touched by the top joint of the middle finger.

How to inject:
For A) and B): i.a., p.a.

- Alternatively:

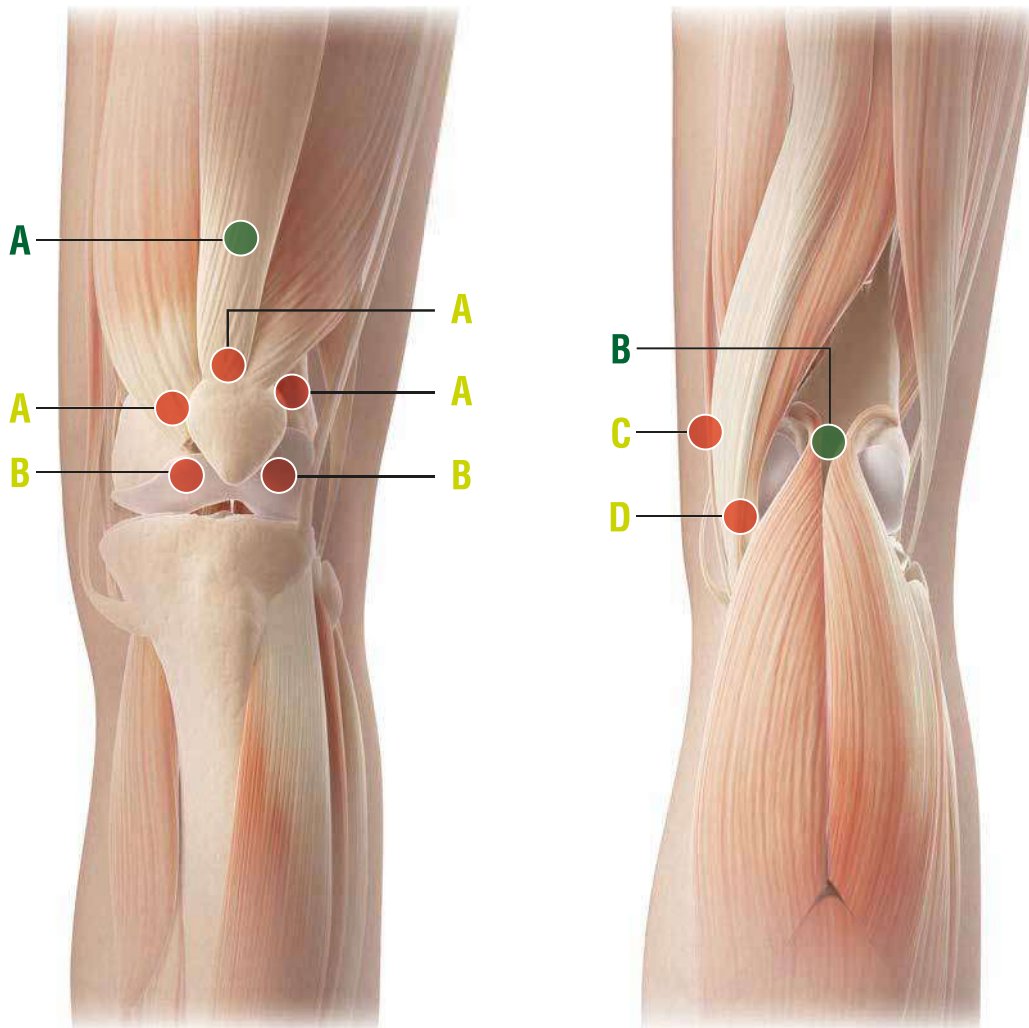
For A) and B): i.m. at a depth of 2 cm; needle inclination towards the hip joint
For C): i.m. at a depth of 1 cm; insert the needle at a 90° degree angle from to the skin surface.

HIP

- Injection in the **main points**

- Hip joint osteoarthritis:
- Hip joint capsule inflammation:
- Hip joint osteoarthritis with rheumatoid arthritis:
- Hip joint pain of muscle origin:
- Hip joint pain of nerve origin (burning hip):
- Hip joint pain due to prolonged bed rest:

KNEE



Remarks:

Subcutaneous (**s.c.**) and intradermal injections: use a 12-16mm, 25-28G needle.

Intramuscular (**i.m.**) injections: use a 40mm, 21G needle

- While making subcutaneous injections, insert the needle at approximately a 45 degree angle (\angle_{45°);
- While making intramuscular injections, insert the needle at approximately a 90 degree angle (\angle_{90°).

The three most common sites of i.a. injections of the knee are: anterolateral, anteromedial (patient positioned with the knee flexed at 90 degrees) and lateral midway of the patella (extended knee).

Intra-articular (**i.a.**) injections: use a 50mm, 21G needle.

● SECONDARY POINTS

Anatomical landmarks:

- A) 4-5 cm above the maximum convexity of the patella
- B) midpoint of the popliteal fossa.

How to inject:
For A) and B): s.c.

● MAIN POINTS

1

Anterior anatomical landmarks:

- A) Top margin of the patella and 2 cm (right and left) from this area follow the curved edge of the patella.
- B) inferior-lateral margin of the patella, at the height of the interspace of the knee joint.

How to inject: s.c. or i.a.
only for lateral A.

2

Posterior anatomical landmarks:

- C) On the inner surface of the knee, at the height of the interspace of the knee joint
- D) On the inner surface of the knee, on the upper edge of the upper end of the tibia, proximal to the joint interspace.

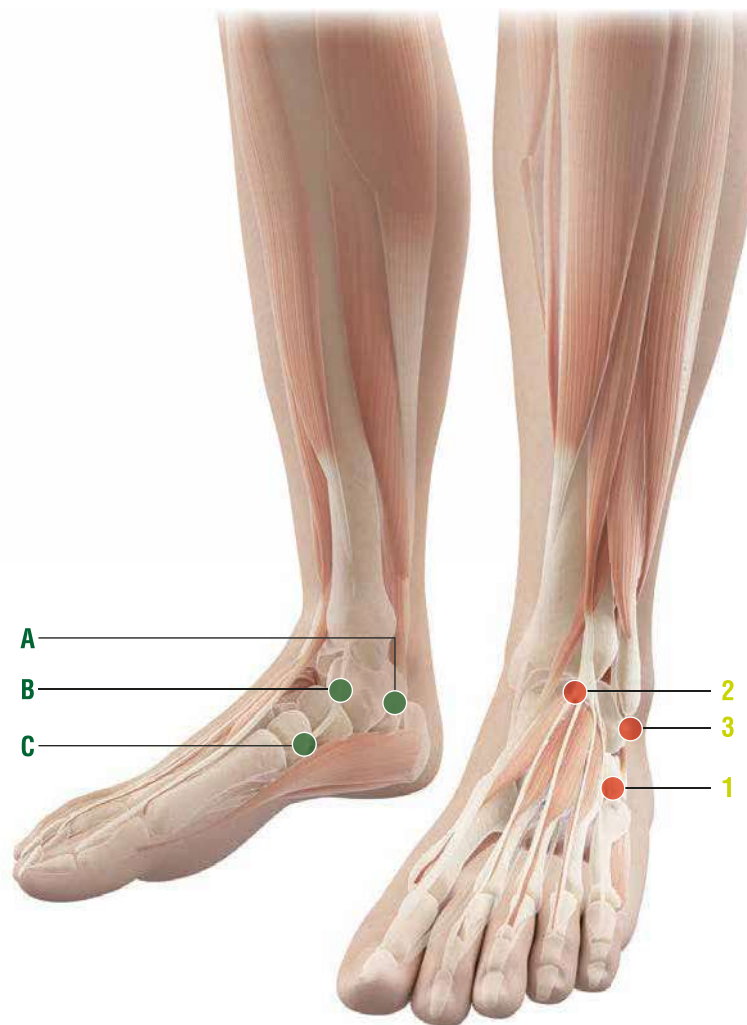
How to inject: s.c., 5-6 mm deep, at a 90 degree angle to the skin surface.

KNEE

- Injection in the **main points**

- Knee arthrosis:
- Painful knee due to rheumatoid arthritis or other autoimmune diseases:
- Knee acute and chronic arthrosynovitis secondary to injury, osteoarthritis or rheumatoid arthritis:
- Arthrosynovitis, acute and chronic post-traumatic or post-surgery arthrosynovitis:
- Traumatic lesions of cruciate or collateral ligaments of the knee:
- Meniscal lesions:
- Knee joint preparation to meniscectomy:
- Maintenance therapy after knee surgery:

ANKLE



Remarks:

Subcutaneous (**s.c.**) injections: 12-16 mm , 25-28 G needle.

- When making subcutaneous injections, insert the needle at approximately a 45 degree angle (\angle_{45°);
- When making intramuscular injections, insert the needle at approximately a 90 degree angle (\angle_{90°).

● SECONDARY POINTS

1

Anatomical landmarks:

- A) 2 cm below and posterior to the medial malleolus, on the upper edge of the heel
- B) On the inner edge of the instep, 2 cm anterior and inferior to the medial malleolus
- C) On the border between the scaphoid and the 1st cuneiform bone.

How to inject: 5 mm, at a 90 degree angle to the skin surface.
Only for B: i.a.

● MAIN POINTS

1

Anatomical landmark:

2 cm anterior and inferior to the external malleolus on the calcaneal-cuboid joint.

How to inject: 5 mm, at a 90 degree angle to the skin surface.

2

Anatomical landmark:

On the central fold of extension of the foot (instep), immediately below the tibia.

How to inject: 5 mm, at a 90 degree angle to the skin surface.

3

Anatomical landmark:

1 cm below and slightly behind the external malleolus, just above the heel.

How to inject: 5 mm, at a 90 degree angle to the skin surface.

ANKLE

- Injection in the **main points**

- Arthrosis pain due to hammer toe:
- Metatarsal pain:
- Metatarsal pain accompanied by Morton's neuroma:
- Rheumatoid arthritis of the foot:
- Foot tendon pain due to prolonged immobilization:

RECOVERTENDO-L



*Bioadapted Hyaluronic Acid (BHA) 20mg
L-Proline 30mg*

Gain Your Power Back!

with **RECOVERTENDO-L**